

RESEARCH ARTICLE

Open Access



Typhlitis induced by *Histomonas meleagridis* affects relative but not the absolute *Escherichia coli* counts and invasion in the gut in turkeys

Mohamed Kamal Abdelhamid^{1,2}, Ivan Rychlik³, Claudia Hess¹, Tamas Hatfaludi^{1,4}, Magdalena Crhanova³, Daniela Karasova³, Julia Lagler^{1,5}, Dieter Liebhart¹, Michael Hess^{1,4} and Surya Paudel^{1*} 

Abstract

Unlike in chickens, dynamics of the gut microbiome in turkeys is limitedly understood and no data were yet published in context of pathological changes following experimental infection. Thus, the impact of *Histomonas meleagridis*-associated inflammatory changes in the caecal microbiome, especially the *Escherichia coli* population and their caecal wall invasion in turkeys was investigated. Birds experimentally inoculated with attenuated and/or virulent *H. meleagridis* and non-inoculated negative controls were divided based on the severity of macroscopic caecal lesions. The high throughput amplicon sequencing of 16S rRNA showed that the species richness and diversity of microbial community significantly decreased in severely affected caeca. The relative abundances of operational taxonomic units belonging to *Anaerotignum lactatifermentans*, *E. coli*, and *Faecalibacterium prausnitzii* were higher and paralleled with a decreased abundances of those belonging to *Alistipes putredinis*, *Streptococcus alactolyticus*, *Lactobacillus salivarius* and *Lactobacillus reuteri* in birds with the highest lesion scores. Although the relative abundance of *E. coli* was higher, the absolute count was not affected by the severity of pathological lesions. Immunohistochemistry showed that *E. coli* was only present in the luminal content of caecum and did not penetrate even severely inflamed and necrotized caecal wall. Overall, it was demonstrated that the fundamental shift in caecal microbiota of turkeys infected with *H. meleagridis* was attributed to the pathology induced by the parasite, which only led to relative but not absolute changes in *E. coli* population. Furthermore, *E. coli* cells did not show tendency to penetrate the caecal tissue even when the intestinal mucosal barriers were severely compromised.

Keywords: *Escherichia coli*, *Histomonas meleagridis*, Turkeys, Caecal microbiota, Inflammation, Penetration

Introduction

A normal gut microbial community and integrity of the intestinal wall in poultry are essential for nutrient digestion, production of beneficial short chain fatty acids and prevention of disease by competitive exclusion or blocking of pathogen colonization [1, 2]. Any shifts of the resident microbiota might compromise

all or some of these functions [3] leading to reduction in intestinal barrier function potentially resulting in bacterial translocation from gut to systemic organs [4, 5]. The knowledge on the composition of complex gut microbiome has enhanced with the application of next generation sequencing [6]. Applying this technique, intestinal microbiota and their interactions with the chicken host have been elucidated in experimental infection models with several pathogens, for instance, infection with *Eimeria tenella* led to relative increase of *Enterobacteriaceae* and decrease of *Lactobacillaceae* [7–10]. Likewise, *Histomonas meleagridis* infection

*Correspondence: Surya.Paudel@vetmeduni.ac.at

¹ Clinic for Poultry and Fish Medicine, Department for Farm Animals and Veterinary Public Health, University of Veterinary Medicine, Vienna, Austria

Full list of author information is available at the end of the article



© The Author(s) 2021, corrected publication 2021. **Open Access** This article is licensed under a Creative Commons Attribution 4.0 International License, which permits use, sharing, adaptation, distribution and reproduction in any medium or format, as long as you give appropriate credit to the original author(s) and the source, provide a link to the Creative Commons licence, and indicate if changes were made. The images or other third party material in this article are included in the article's Creative Commons licence, unless indicated otherwise in a credit line to the material. If material is not included in the article's Creative Commons licence and your intended use is not permitted by statutory regulation or exceeds the permitted use, you will need to obtain permission directly from the copyright holder. To view a copy of this licence, visit <http://creativecommons.org/licenses/by/4.0/>. The Creative Commons Public Domain Dedication waiver (<http://creativecommons.org/publicdomain/zero/1.0/>) applies to the data made available in this article, unless otherwise stated in a credit line to the data.

resulted in reduced gut microbial richness and diversity favouring caecal colonization of avian pathogenic *Escherichia coli* in chicken layers [4]. In turkeys, such studies are still limited and dynamics of enteric microbiota, especially in the presence of inflammation and necrosis remains to be understood. Previous studies in turkeys focused on characterization of the microbiota along the gastrointestinal tract or decipher changes induced by antibiotic treatment, different litter management or natural infection with haemorrhagic enteritis virus [11–14]. Additional studies associated composition of turkey gut microbiota with production of short chain fatty acids in the gut or increase in the body weight [15–17].

Escherichia coli is a Gram-negative bacterium, a member of the *Enterobacteriaceae* and resides in the lower digestive tract of chickens and turkeys where it colonizes in the first 24 h post-hatching [18, 19]. Avian colibacillosis caused by *E. coli* is reported to be responsible for fibrinous peritonitis, hepatitis, polyserositis in turkeys and causing economic losses [20, 21]. Furthermore, some of the *E. coli* isolates from clinical cases of turkey cellulitis were characterized to be avian pathogenic *E. coli* based on the presence of virulence associated genes and phylogenetic groups [22]. Although the demarcations between pathotypes are not very clear, some of the intestinal commensals might carry virulence associated genes and the isolates could show opportunistic or potentially pathogenic nature in birds [23]. In contrast to chickens, experimental and field studies related to *E. coli* infection in turkeys are very scarce. The majority of experimental studies in turkeys involved respiratory routes of infection and were focused to elucidate the impact of stress factors or other co-residing pathogens in the progression of *E. coli* infection [24–27]. Thus, the relationship between *E. coli* populations residing in the gut and systemic bacteremia in turkeys is largely unknown.

Histomonas meleagridis, a protozoal parasite is very well known to cause severe inflammation and necrosis in caeca and liver of experimentally infected turkeys, and in vitro mutual interaction of *E. coli* with the parasite has been shown previously [28]. In addition, in a previous co-infected model in chicken layers, *H. meleagridis* enhanced the penetration of *E. coli* throughout the caecal tissue [4]. The present study was therefore conducted in turkeys with the following two main objectives: (i) to investigate the dynamics of intestinal *E. coli* population and a possible microbial shift related to the pathology induced by *H. meleagridis* infection in the gut, and (ii) to assess the consequences of inflammation and necrosis on caecal wall penetration with *E. coli* and their systemic translocation.

Materials and methods

Birds and housing

Thirty-three one-day-old commercial Hybrid Converter turkeys (Hendrix Genetics, Boxmeer, the Netherlands) were randomly divided into four groups (Table 1). Each group of birds was placed in a separate negatively pressured room on deep litter.

Preparation of *H. meleagridis* cultures for inoculation

The virulent (in vitro passage of 28 times) or attenuated (in vitro passage of 301 or 302 times) clonal culture of *H. meleagridis*/Turkey/Austria/2922-C6/04 co-cultivated with the bacterial strain *E. coli* DH5 α , as a supplement for propagation of the parasite [28] was used for inoculation. The inocula medium consisted of Medium 199 with Earle's salts, L-glutamine, 25 mM HEPES and L-amino acids (Gibco™ Invitrogen, Austria), 15% fetal calf serum (Gibco™ Invitrogen) and rice starch, 0.25% (w/v) (Sigma-Aldrich, Vienna, Austria). The number of viable attenuated and virulent *H. meleagridis* cells was determined using trypan blue stain and a Neubauer hemocytometer

Table 1 Design of the animal experiment

Group	Experimental inoculation (days of life)		Necropsy and sampling (days of life)		
	1	28	35	42	49
Negative control (n = 9)	<i>E. coli</i> DH5 α	<i>E. coli</i> DH5 α	3 ^a	3	3
Vaccinated (n = 9)	No	Attenuated <i>H. meleagridis</i> co-cultivated with <i>E. coli</i> DH5 α	3	3	3
Infected (n = 6)	No	Virulent <i>H. meleagridis</i> co-cultivated with <i>E. coli</i> DH5 α	3	3	NA ^b
Vaccinated + infected (n = 9)	Attenuated <i>H. meleagridis</i> co-cultivated with <i>E. coli</i> DH5 α	Virulent <i>H. meleagridis</i> co-cultivated with <i>E. coli</i> DH5 α	2 ^c	3	3

^a Number of necropsied birds at each time point.

^b Not applicable.

^c One bird showed swollen hock joints and was euthanized prior to the necropsy date.

(Sigma-Aldrich, St. Louis, MO, USA) to adjust the appropriate number in each inoculum. For *E. coli* DH5 α , colony-forming units (CFU) were counted from serial dilutions of the inoculum on coliform agar plates after incubation at 37 °C for 24 h.

Experimental design

As illustrated in Table 1, different groups of birds were treated as follows: control birds ($n = 9$) were inoculated with culture media containing only 7.2×10^6 CFU and 1×10^7 CFU of *E. coli* DH5 α at 1 and 28 days of life, respectively; vaccinated birds ($n = 9$) were inoculated with 6×10^5 cells of attenuated *H. meleagridis* (passage 301) co-cultured with 1.2×10^8 CFU of *E. coli* DH5 α at 28 days of life; infected birds ($n = 6$) were inoculated with 6×10^5 cells of virulent *H. meleagridis* (passage 28) co-cultured with 9.9×10^7 CFU of *E. coli* DH5 α at 28 days of life; vaccinated + infected birds ($n = 9$) were inoculated with 6×10^5 cells of attenuated *H. meleagridis* (passage 302) co-cultured with 1.2×10^8 CFU of *E. coli* DH5 α and 6×10^5 cells of virulent *H. meleagridis* (passage 28) co-cultured with 9.9×10^7 CFU of *E. coli* DH5 α at 1 and 28 days of life, respectively. All inocula were administered via oral and cloacal routes, and the procedures were followed as described previously [29]. The birds were examined daily for clinical signs. Necropsy and sampling were performed in three birds from each group at 7 and 14 days post *H. meleagridis* infection (dpi), with an exception at 7 dpi when only two birds were killed from the vaccinated + infected birds. Finally, at 21 dpi, the remaining three birds from each group were killed and sampled, except from the infected group where no birds were left for necropsy.

Macroscopic lesions in caeca

During necropsy, macroscopic lesions in caeca were recorded and lesion scores (LSs) were assigned based on the previously published scoring scheme ranging from 0 to 4 [30].

Microscopic examination

Caecal tissues from all birds were fixed in 10% neutral buffered formalin, dehydrated, embedded in paraffin, sectioned at 5 μ m thickness and stained with hematoxylin and eosin.

Bacteriology

For the quantification of bacterial load of *E. coli* in caecum, liver and spleen, samples were collected from all birds during necropsy, homogenized and tenfold serial dilution suspensions in phosphate-buffered saline (PBS) were plated on MacConkey agar (Neogen, Heywood, UK) plates in duplicates. Following incubation of plates at

37 °C for 24 h, *E. coli* CFUs were counted and the bacterial loads were calculated as CFU/g of respective organs.

Microbiota analysis

Caecal contents from each bird were collected in sterile 1.5 mL tubes during necropsy. In case lesions were confined to one side, caecal content of the affected caeca was collected. All samples were stored at -80 °C until further processing. Caecal content was homogenized in a MagNALyzer (Roche). Following homogenization, the DNA was extracted using a QIAamp DNA Stool Mini Kit according to the manufacturer's instructions (Qiagen, Germany). The DNA concentration was determined with a spectrophotometer and samples diluted to 5 ng/mL were used as a template in PCR with forward primer 5'-TCGTCGGCAGCGTCAGATGTGTATAAAGAGACAG-MID-GT-CCTACGGGNGGCWGCAG-3' and reverse primer 5'-GTCTCGTGGGCTCGGAGATGTGTATAAGAGACAG-MID-GT-GACTACHVGGGTATCTAATC-C-3'. The sequences in italics served for index ligation whereas the underlined sequences allowed for amplification over the V3/V4 region of 16S rRNA genes. MIDs represent different sequences of 5, 6, 7, or 9 base pairs in length which were used to identify individual samples after the whole sequencing run. PCR amplification was performed using a KAPA HiFi Hot Start Ready Mix kit (Kapa Biosystems) and the resulting PCR products were purified using AMPure beads. In the next step, the PCR product concentration was determined with a spectrophotometer before the DNA was diluted to 100 ng/ μ L and groups of 14 PCR products with different MID sequences were indexed with the same index from Nextera XT Index Kit following the manufacturer's instructions (Illumina). The next set of 14 PCR products with different MID sequences were indexed with the next index from the Nextera XT Index kit thus allowing an increase in the number of samples analyzed in a single sequencing run. Prior to sequencing, the concentration of differently indexed samples was determined using a KAPA Library Quantification Complete kit (Kapa Biosystems). All indexed samples were diluted to 4 ng/ μ L and 20 pM phiX DNA was added to a final concentration of 5% (v/v). Sequencing was performed using MiSeq Reagent Kit v3 (600 cycle) and MiSeq apparatus according to the manufacturer's instructions (Illumina). Quality trimming of the raw reads was performed using TrimmomaticPE v0.32 with sliding window 4 bp and quality read score equal or higher than 20 [31]. Minimal read length must have been at least 150 bp. The fastq files generated after quality trimming were uploaded into QIIME software [32]. Forward and reverse sequences were joined and in the next step chimeric sequences were predicted and excluded by the slayer algorithm. The resulting

sequences were then classified by RDP Seqmatch with an OTU (operational taxonomic unit) discrimination level set to 97%.

Immunohistochemistry

In order to investigate the colonization and penetration of caecal tissues by *E. coli*, paraffin embedded samples of caeca from all birds were processed for immunohistochemistry. Further, to validate the findings from the actual study, caeca of 14 turkeys from infected groups with monoxenic ($n = 8$) or xenic ($n = 6$) cultures of *H. meleagridis* and control birds ($n = 4$) from previously published experiments were included [29, 33]. Likewise, caecal samples of naturally infected turkeys showing severe fibrinous typhilitis from two field cases were also considered. The IHC protocol for the detection of *E. coli* was followed as described previously [4]. Briefly, tissue sections mounted on charged glass slides were dewaxed, rehydrated and incubated overnight with a primary monoclonal antibody (anti-*E. coli* antibody (2D7/1), ab35654, Abcam, Austria). Following incubation, slides were washed with PBS and biotinylated anti-mouse IgG antibody (Vector Laboratories, Austria) was added. Then the vectastain ABC Kit and DAB substrate kit (Vector Laboratories) were used for visualizing the bound antibody. Finally, the sections were counter-stained with Mayer's haematoxylin (Merck KGaA, Austria) and observed under a microscope.

Statistical analysis

Data of alpha diversity matrices and *E. coli* count were analyzed by one-way ANOVA followed by Tukey's multiple comparison post hoc test. The Spearman's rank correlation coefficient (r) was used to evaluate relationship between caecal LSs and *E. coli* count in the caecum. All analyses were performed in SPSS (IBM® SPSS® version 25; IBM cooperation, New York, USA). The p value < 0.05 was considered as statistically significant.

Results

Clinical signs

One bird from the vaccinated + infected group showed swollen hock joints and was euthanized before scheduled killing. No clinical signs were seen in rest of birds.

Macroscopic lesions

The early-euthanized bird with swollen hock joints showed arthritis. The control birds that were not inoculated with *H. meleagridis* were devoid of pathological lesions similar to those which received attenuated histomonads (LS 0, Figure 1A). Following inoculation of birds with attenuated and/or virulent *H. meleagridis* strains, severity of caecal lesions varied, and LS 0, 1, 3 and 4

were recorded (Figures 1B–D). Therefore, birds were categorized into four groups according to their inoculation status and severity of caecal lesions for the analysis of sequencing, bacteriology and IHC data (Table 2). These groups were as follows: (i) negative control ($n = 9$; birds not inoculated with *H. meleagridis*, LS 0), (ii) no lesion ($n = 11$; birds inoculated with *H. meleagridis* that showed LS 0), (iii) mild lesion ($n = 6$; birds inoculated with *H. meleagridis* that showed LS 1), and (iv) severe lesion ($n = 6$; birds inoculated with *H. meleagridis* that showed LS 3 or 4). Negative control birds were separated from *H. meleagridis* inoculated birds with no lesion to observe possible differences induced by parasite inoculation. The presence of compact fibrinous mass in the lumen of one or both caeca are allocated in the macroscopic LS 3 or LS 4 [30]. As the samples were always taken from the affected caecum, birds showing LS 3 and 4 were grouped together.

Histopathology

No histological lesions were found in caeca of birds from negative control and no lesion groups (Figures 2A and B). Birds belonging to the mild lesion group showed mucosal erosion with heterophilic/eosinophilic infiltration limited to lamina propria and submucosa (Figure 2C). Severe necrosis in mucosa with inflammatory cells extended transmurally was observed in birds assigned to the severe lesion group (Figure 2D).

Bacteriology

Pure colonies of *Streptococcus* sp. were isolated from the affected joint of the early euthanized bird. Average bacterial counts of *E. coli* in caeca of birds from different groups ranged from 8 to 9 log CFU/g and differences among groups were not statistically significant (Figure 3A). Although a very slight tendency of positive correlation was observed between the severity of caecal macroscopic LSs and the *E. coli* load but this was not statistically significant ($r = 0.11$; Figure 3B). In systemic organs, one bird from the negative control group was positive in spleen and contained 1.56 log CFU/g of *E. coli*. In another bird from the no lesion group that was inoculated with attenuated *H. meleagridis*, liver and spleen were found positive with 3.1 log CFU/g and 3 log CFU/g of *E. coli*, respectively.

Caecal microbiota

The OTUs identified in caecal samples were classified into 13 bacterial phyla and one archaeal phylum. Overall *Firmicutes* (78.2%), *Bacteroidetes* (13.3%), *Acidobacteria* (7.4%), *Verrucomicrobia* (4.8%) and *Proteobacteria* (3.4%) were the most dominant phyla (Figure 4).

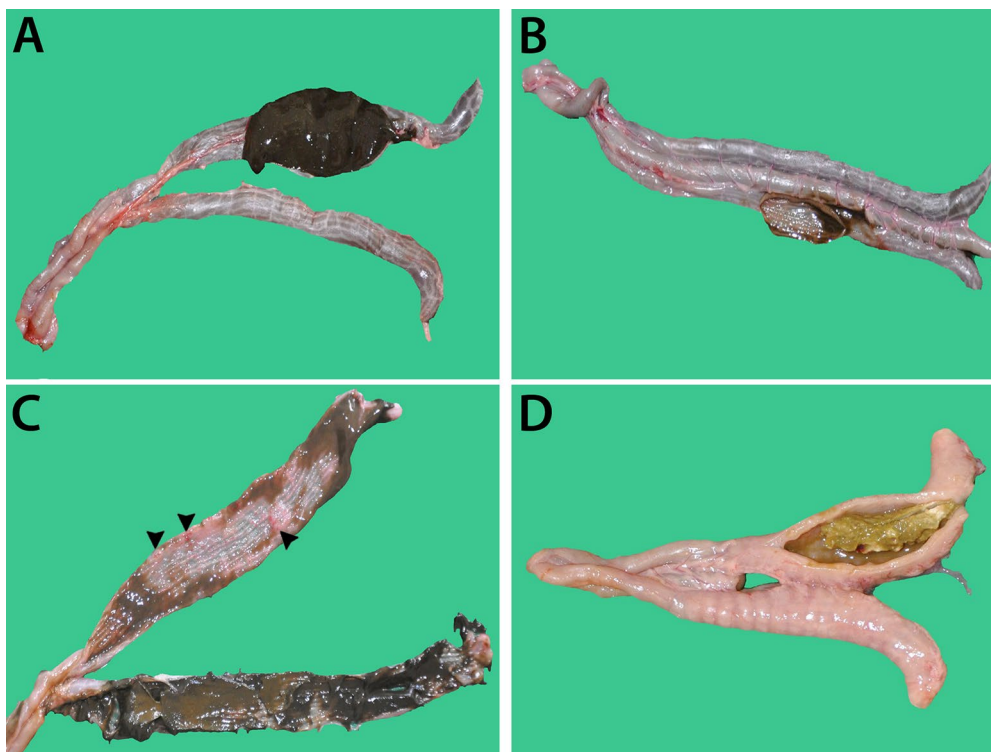

Figure 1 Macroscopic lesions in caecum of turkeys in different groups. **A** Negative control group, not inoculated with *H. meleagridis*; **B** no lesion group, inoculated with *H. meleagridis*; **C** mild lesion group, inoculated with *H. meleagridis* (hemorrhages are shown with arrow heads); **D** severe lesion group, inoculated with *H. meleagridis*.

Table 2 Number of turkeys in different groups based on the severity of macroscopic lesions in caecum for the analysis of microbiota, *E. coli* count and immunohistochemistry data

Treatment	Group			
	Negative control (n = 9)	No lesion (n = 11)	Mild lesion (n = 6)	Severe lesion (n = 6)
Negative control	9	0	0	0
Vaccinated	0	9	0	0
Infected	0	0	3	3
Vaccinated + infected ^a	0	2	3	3

^a One bird was euthanized prior to the scheduled necropsy date, thus is excluded from the total of this group.

Bacterial diversity and richness was evaluated among the four groups (negative control, no lesion, mild lesion and severe lesion) using alpha diversity indices (Observed species, Chao 1, Shannon index and Equability). Bacterial diversity and richness significantly decreased in birds of the severe lesion group compared to others (Figures 5A–D).

The relative abundance of OTUs was analysed at species level and, where possible, confirmation of species was done by aligning with available sequences using nucleotide BLAST or RNA/ITS databases. Out of 15 most abundant bacterial species, the relative abundance of *Anaerotignum lactatifermentans*, *E. coli*, *Faecalibacterium prausnitzii*, *Akkermansia muciniphila*, *Caecibacterium sporiformans*, *Clostridium leptum* and *Butyrivibrio pullicaecorum* were more abundant in birds of the severe lesion group in comparison to other groups. In contrary, *Alistipes putredinis*, *Streptococcus alactolyticus*, *Lactobacillus salivarius*, *Lactobacillus reuteri* were less abundant in birds with the highest lesion scores (Figure 6).

Immunohistochemistry

E. coli cells were detected in caecal luminal content of one and three birds from the mild lesion and the severe lesion groups, respectively (Table 3). *E. coli* did not penetrate into the caecal wall of birds from any of the groups (Figures 7A and B). In samples taken from previously published experimental studies [29, 33], *E. coli* cells were detected in the luminal content of 3 out of 8 turkeys inoculated with monoxenic *H. meleagridis*

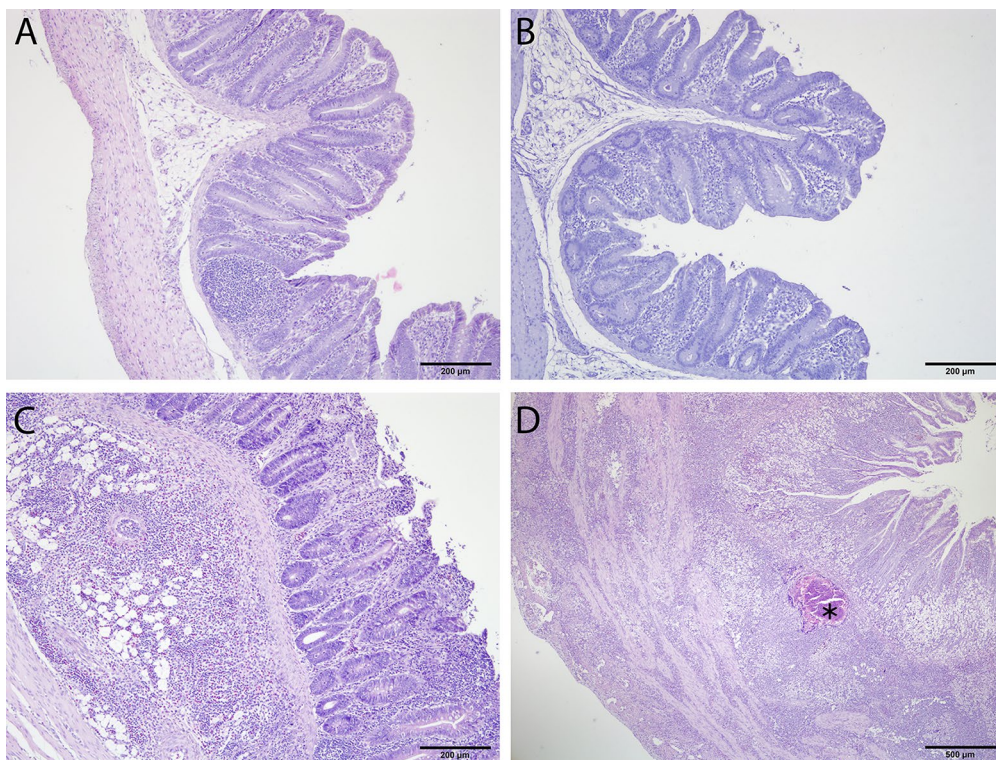


Figure 2 Histopathology in caecum of turkeys in different groups. **A** Negative control group, not inoculated with *H. meleagridis*, tissues are normal; **B** no lesion group, inoculated with *H. meleagridis*, tissues are normal; **C** mild lesion group, inoculated with *H. meleagridis*, erosion of mucosal epithelium with heterophilic/eosinophilic cells infiltration extended to submucosa; **D** severe lesion group, inoculated with *H. meleagridis*, extensive necrosis with pyogranulomatous reaction (asterisk) and transmural infiltration of inflammatory cells.

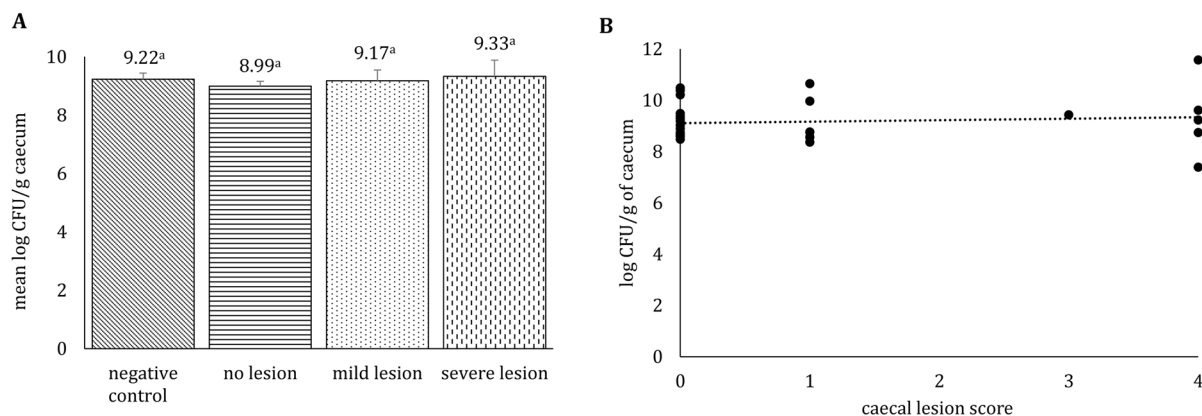
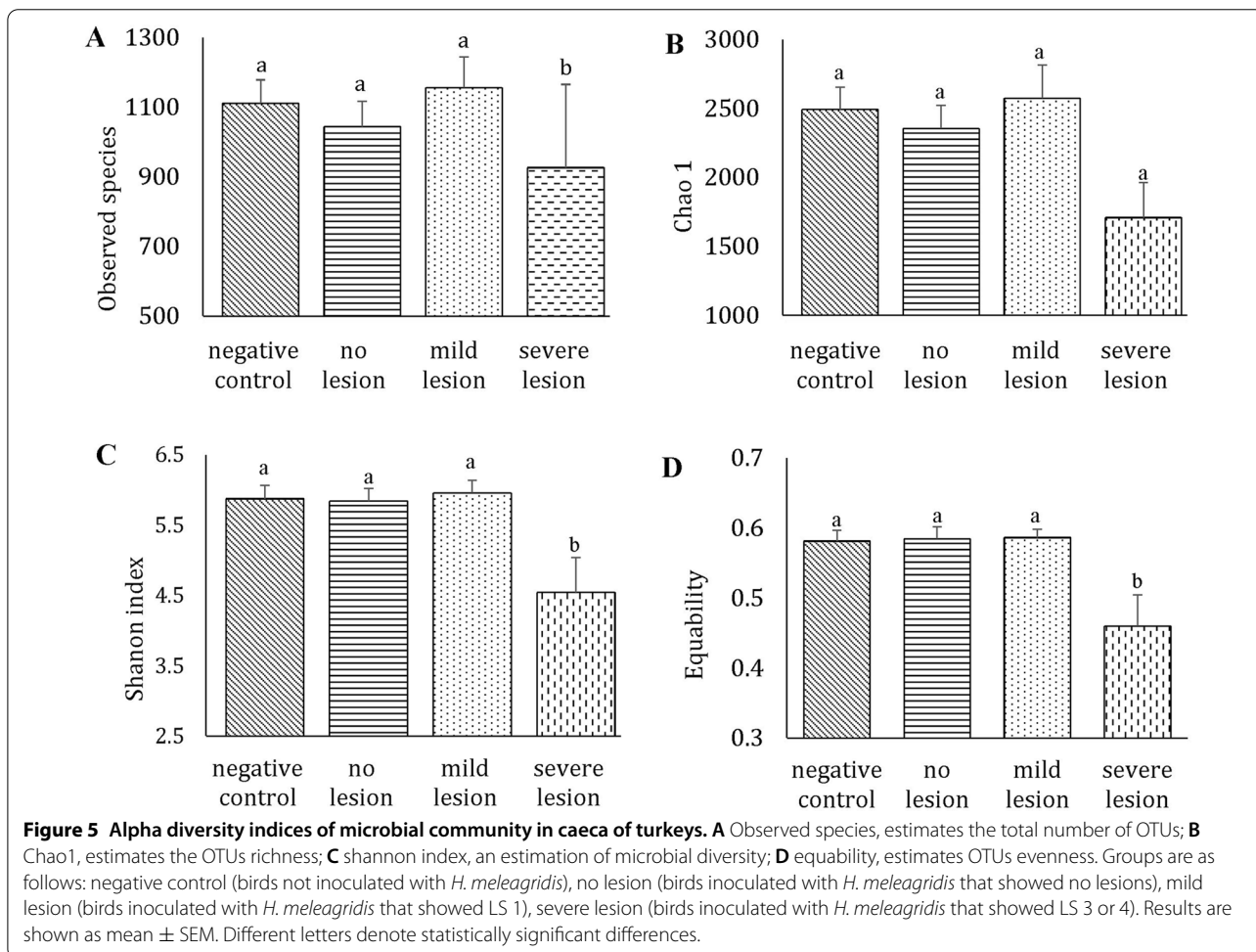
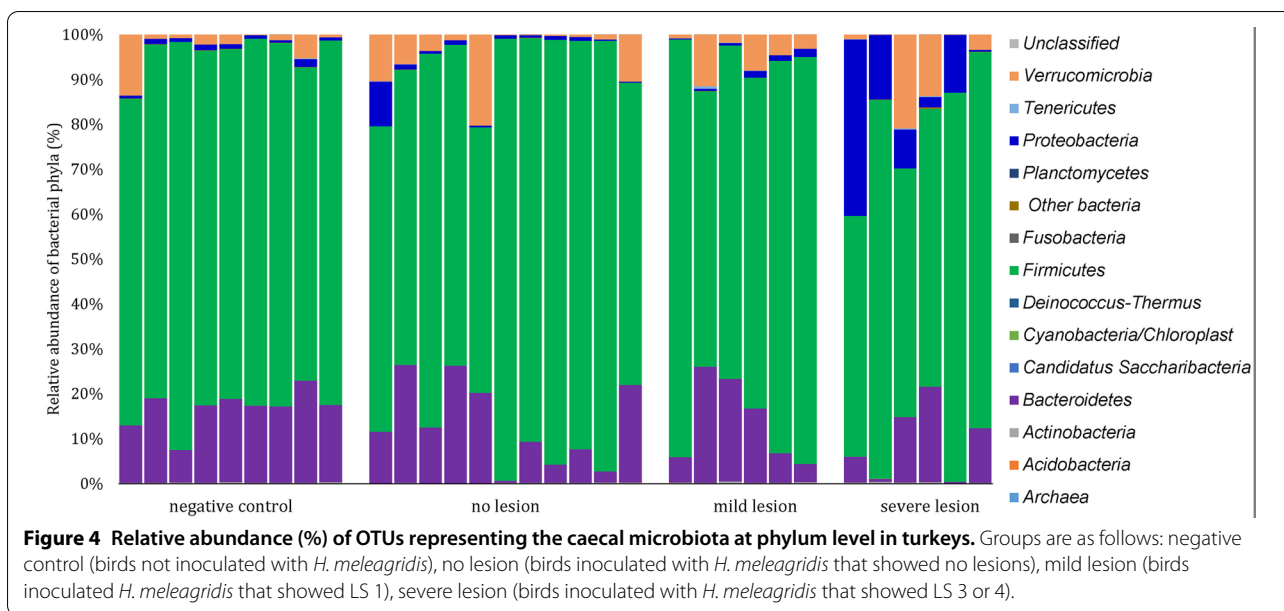


Figure 3 Average *E. coli* counts (**A**) and their correlation with the severity of macroscopic lesions (**B**) in caeca of turkeys. **A** Groups are as follows: negative control (birds not inoculated with *H. meleagridis*), no lesion (birds inoculated with *H. meleagridis* that showed no lesions), mild lesion (birds inoculated with *H. meleagridis* that showed LS 1), severe lesion (birds inoculated with *H. meleagridis* that showed LS 3 or 4). Results are expressed as mean±SEM, values with different letters are statistically significant; **B** Spearman's correlation coefficient of caecal lesion score with bacterial load of *E. coli* count in caeca. Lesion scores were assigned based on the previously published scoring scheme [31].

culture (Figure 7C) and in 4 out of 6 turkeys inoculated with xenic *H. meleagridis* culture, in which some *E. coli* cells were attached on the necrotic epithelium

of the caecal mucosa (Figure 7D). None of the samples from both trials showed infiltration of *E. coli* in the caecal wall. Likewise, caecal content and necrotic



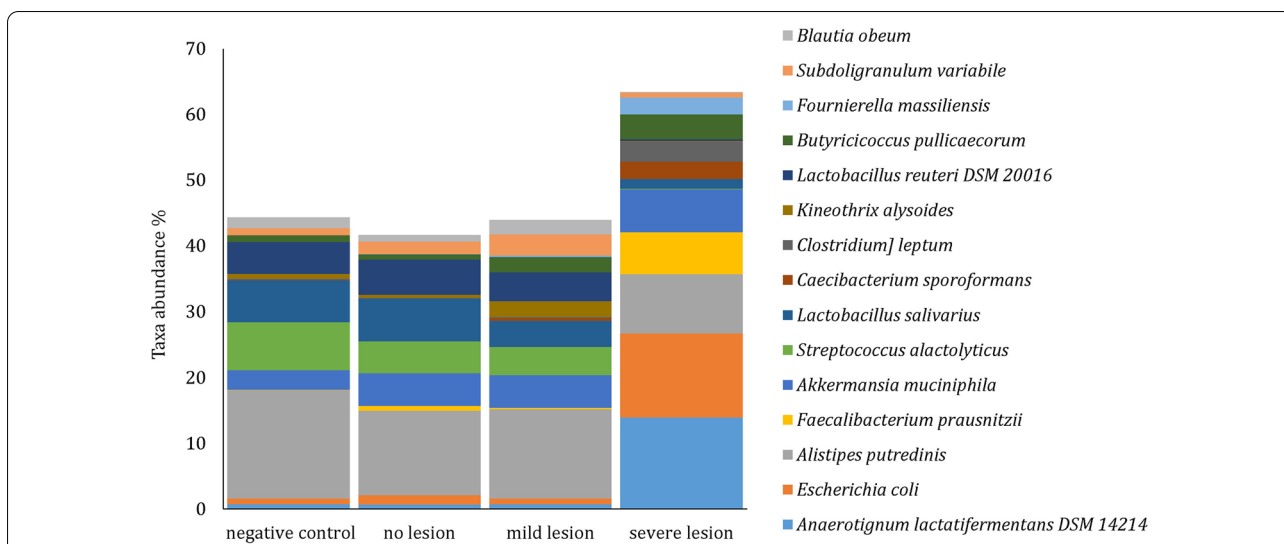


Figure 6 Mean relative abundance (%) of the 15 most abundant bacterial species in caeca of turkeys. Groups are as follows: negative control (birds not inoculated with *H. meleagridis*), no lesion (birds inoculated with *H. meleagridis* that showed no lesions), mild lesion (birds inoculated with *H. meleagridis* that showed LS 1), severe lesion (birds inoculated with *H. meleagridis* that showed LS 3 or 4).

Table 3 Detection of *E. coli* with immunohistochemistry in the caecum of turkeys

Sample type	Caecal lumen (content)	Caecal wall
Infected with monoxenic <i>H. meleagridis</i> (actual trial) ^a		
Negative control (n = 9)	_b	-
No lesion (n = 11)	-	-
Mild lesion (n = 6)	1 ^c	-
Severe lesion (n = 6)	3	-
Infected with monoxenic <i>H. meleagridis</i> [29]		
Negative control (n = 2)	-	-
LS 2 (n = 1)	-	-
LS 3 (n = 3)	2	-
LS 4 (n = 4)	1	-
Infected with xenic <i>H. meleagridis</i> [33]		
Negative control (n = 2)	-	-
LS 3 (n = 1)	1	-
LS 4 (n = 5)	3 (caecal content and/or necrotic mucosal epithelium)	-
Field cases with histomonosis		
n = 2	2 (caecal content and necrotic mucosal epithelium)	-

^a For group allocation, refer to Table 2.

^b Negative.

^c Number of positive samples.

epithelium of mucosal surface were positive for *E. coli* while layers of caecal wall were negative in samples taken from field cases of histomonosis in turkeys (Figure 7E).

Discussion

The gut is the reservoir for *E. coli* in poultry and the features of the bacterial population in intestine has been largely explored in chickens [2]. It is well known that

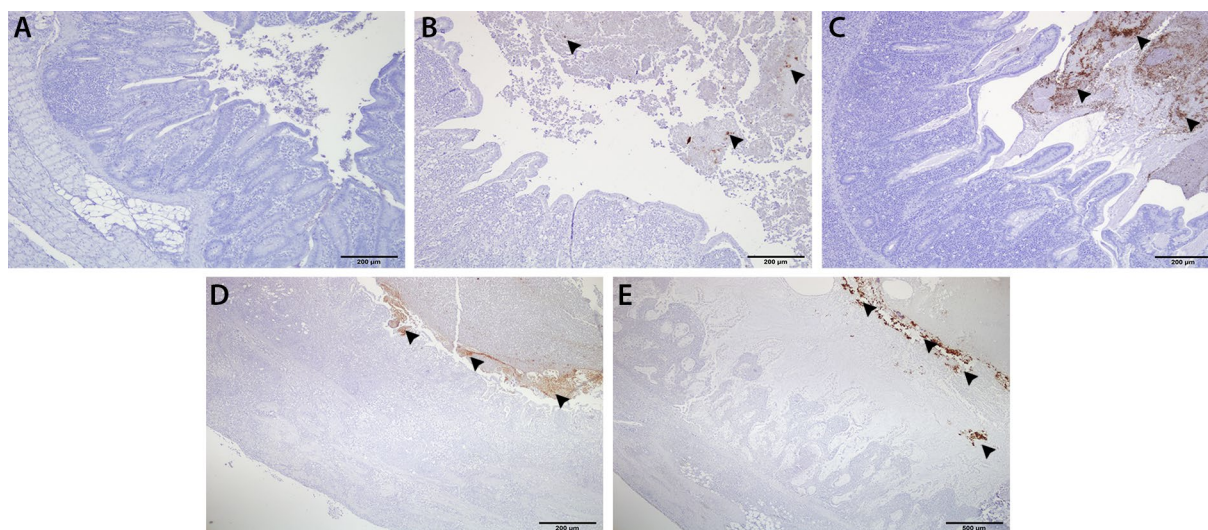


Figure 7 Immunohistochemical detection of *E. coli* in the caecal samples of turkeys. **A** Negative control, absence of immunostaining for *E. coli*; **B** presence of *E. coli* in the caecal content (arrow heads) of a sample from the severe lesion group that was infected with *H. meleagridis*; **C–E** profound presence of *E. coli* (arrow heads) in the caecal content without any infiltration into the caecal wall, caeca are severely inflamed and necrotized after experimental infection with monoxenic *H. meleagridis* culture (**C**), xenic *H. meleagridis* culture (**D**) natural infection from a field case **E**.

inflammation and necrosis caused by gut pathogens in chickens can substantially affect the structure of gut microbiota. However, such studies are lacking in turkeys. *H. meleagridis* is a well-recognized protozoal parasite that can cause severe caecal tissue destruction in turkeys and the relationship between *H. meleagridis* and *E. coli* is also evident in vitro [34]. Thus, in the present study, *H. meleagridis* was taken as a model organism to investigate the influence of pathology-associated changes on the caecal microbiota with particular attention to *E. coli*. In order to extend this subject, the ability of *E. coli* to invade the caecal wall was also investigated.

Quantification of the total *E. coli* counts among different groups showed that there was no association between the load of *E. coli* and the pathologies in the gut. The finding is in agreement with a previous study in mice where inflammation and disease severity did not influence the number of *E. coli* [35]. However, a link could be determined between severity of gut inflammation and microbiota composition. The pathology induced by *H. meleagridis* was associated with the pronounced shift in microbial structure, microbial richness and diversity. Similar effects were noticed in chickens that were either co-infected with *H. meleagridis* and avian pathogenic *E. coli* [4] or with *E. tenella* [36, 37]. In controversy, in a different study with *E. tenella* infection in broiler chickens, no changes were reported in alpha diversity even in caecal samples with the highest lesion scores [10]. This discrepancy between studies can be due to different factors

such as inoculated pathogen, host, age, stocking density or gender; all have been shown to influence the microbiome composition and diversity [38].

The relative abundance of OTUs belonging to *Anaerotignum lactatifermentans*, *E. coli* and *Faecalibacterium prausnitzii* increased in caecal samples of birds allocated in the severe lesion group. The higher relative abundance of *Anaerotignum lactatifermentans*, amino acid decomposing bacterium, in birds with severe lesions may be attributed to the fibrinous necrotic enteritis [39, 40]. Fibrinous inflammation usually occurs when vasculature fluid leaks allowing large plasma proteins, especially fibrinogen, to enter the tissue [41]. Furthermore, fibrinonecrotic compact mass in caecum blocks the digesta to pass from small intestine and this might result into increased retention time and ultimately flourish the population of proteolytic bacteria [42].

The increase in relative abundance of phylum *Proteobacteria*, in particular *E. coli* population, in birds of the severe lesion group is obviously an indication of gut dysbiosis induced by inflammation and necrosis. However, the high throughput sequencing identifies the overall microbial communities and their relative abundance to each other, in which every decrease in one taxon's abundance leads to an equivalent increase across the remaining taxa while CFU count determines the absolute bacterial load. Therefore, building up biological interpretations depending only on sequencing data might be misleading as the measurement of each taxon's relative

abundance is dependent on the populations of all other taxa. The enrichment in one bacterial taxa (high relative abundance) does not necessarily reflect the outgrowth of this taxa (actual abundance) [43]. The phenomenon is nicely reflected by the absolute and relative population of *E. coli* in this study. Absolute counts of *E. coli* did not differ across all groups of birds. Relative increase of *E. coli* in birds with severe lesions is therefore a consequence of minimizing other taxa and not *E. coli* overgrowth. Nevertheless, as stated above, it is interesting that *E. coli* maintains the same population in turkeys with or without gut inflammation. Likewise, the relative abundance of *Faecalibacterium prausnitzii*, a potentially beneficial microbe was strongly increased in birds belonging to the severe lesion group. Increase of *Faecalibacterium prausnitzii*, was associated also with an increase of closely related *Fournierella massiliensis* suggesting that the observation was not an artefact. *Faecalibacterium prausnitzii* is an anti-inflammatory commensal bacteria [44] thus, the increased relative abundance of this species in the condition with the highest lesion score might be due to a beneficial response against inflammation [45]. A specific feature of *Faecalibacterium prausnitzii* is the loss of spore formation [46, 47] with alternative measures to cope with oxygen. *Faecalibacterium prausnitzii* is capable to grow at microaerophilic conditions [48] which may enable this bacterium to survive local inflammation associated with generation of oxygen radicals by macrophages and heterophils. Moreover, its ability to produce butyrate and its location in the mucous layer near the epithelial cells [49] might enable it to share an ecological niche with *E. coli* and also suppress expansion of pathosymbionts to colonize the mucus layer, however it needs to be further investigated in details.

Lactobacillus as a probiotic has been shown to control disease aggravation via modulation of the innate and acquired immune system [50, 51]. Therefore, the high abundance of *Lactobacillus salivarius* and *reuteri* in relatively healthy birds (negative control, no lesion and mild lesion groups) compared to those in severe lesion group with LS 3 or 4 might have contributed to an early immune response, reducing the invasion of *H. meleagridis* and opportunistic pathogenic bacteria along epithelial cells. *Lactobacilli* were observed to be the predominant microbes in the small intestine of chickens and turkeys [52, 53]. Therefore, decreased *Lactobacillus* abundance in birds with typhlitis could also be due to the blockage of digesta from small intestine because of compact fibrino necrotic mass in the caecum. The same explanation can be stated for *Streptococcus alactolyticus*, which was also detected with high relative abundance in negative control birds and abundance decreased in infected birds with lesions.

With IHC, *E. coli* could only be detected in luminal content of caecum and preserved caecal content (coagula). Low numbers of *E. coli* positive caecal samples in the actual study can be explained by the fact that routine steps in tissue processing for paraffin sections might remove contents from the gut as previously reported [54]. Anyhow, it is interesting to observe that *E. coli* cells did not infiltrate into the caecal wall even in birds with high relative abundance of *E. coli* and severe sloughing of mucosal epithelium. Similar findings in turkeys from other experimental studies and field cases showed that the pattern remains the same in birds experimentally infected with monoxenic or xenic *H. meleagridis* cultures or in those that are naturally infected. Altogether, it was demonstrated that *E. coli* in the gut of turkeys do not show a tendency to penetrate the gut wall and the effect was not potentiated by the presence of inflammation and necrosis. Very limited re-isolation of *E. coli* from systemic organs with no definite pattern based on severity of lesions indicated absence of systemic translocation of *E. coli* from the gut.

The significant dysbiosis in the caecal microbiota of turkeys was correlated with the severity of pathology following *H. meleagridis* infection. This perturbation was associated with increased relative abundance but not an absolute count of *E. coli* in the gut. Inflammation and necrosis due to *H. meleagridis* did not provoke penetration of caecal wall and systemic translocation of *E. coli* from the gut. Thus, intestinal *E. coli* cells in turkeys do not seem to have a tendency to cause systemic bacteremia even when the gut barrier is compromised.

Abbreviations

CFU: Colony forming units; Dpi: Days post *H. meleagridis* infection; *E. coli*: *Escherichia coli*; *H. meleagridis*: *Histomonas meleagridis*; *E. tenella*: *Eimeria tenella*; IHC: Immunohistochemistry; LS: Lesion score; OTU: Operational taxonomic unit; PBS: Phosphate buffered saline; PCR: Polymerase chain reaction.

Acknowledgments

The authors are thankful to Delfina Jandreski-Cvetkovic and Claudia Ibesich for their technical input. We also thank Fana Alem Kidane for providing some samples for immunohistochemistry.

Authors' contributions

CH, DL, MH and SP conceived and designed the study; MKA, CH, JL, DL and SP performed the animal trial and sampling; TH prepared the *H. meleagridis* cultures; MKA, CH and SP performed the bacteriological investigation; MKA, DL and SP performed the histological investigation; IR, MC and DK prepared the samples and conducted sequencing analysis; MKA and SP prepared the first draft and all the authors provided their inputs in the manuscript. All authors read and approved the final manuscript.

Funding

The study was partially funded by the European Regional Development Fund, Cross-border Cooperation Programme INTERREG V-A Austria-Czech Republic of the European Union, project number: ATCZ194, INPOMED (Innovations in Poultry Medicine). Open access funding provided by University of Veterinary Medicine Vienna.

Availability of data and materials

Raw sequence reads were uploaded to the NCBI BioProject databank (PRJNA718176).

Declarations**Ethics approval and consent to participate**

The trial was approved by the institutional ethics and animal welfare committee and the national authority according to §§ 26ff. of Animal Experiments Act, Tierversuchsgesetz 2012–TVG 2012 (License Number GZ.68.205/0161-WF/V/3b/2017).

Competing interests

The authors declare that they have no competing interests.

Author details

¹Clinic for Poultry and Fish Medicine, Department for Farm Animals and Veterinary Public Health, University of Veterinary Medicine, Vienna, Austria. ²Department of Pathology, Faculty of Veterinary Medicine, Beni-Suef University, Beni-Suef, Egypt. ³Department of Immunology, Veterinary Research Institute, 62100 Brno, Czech Republic. ⁴Christian Doppler Laboratory for Innovative Poultry Vaccines (IPOV), University of Veterinary Medicine, Vienna, Austria. ⁵Present Address: Section of Immunology, Vetsuisse Faculty, University of Zurich, Zurich, Switzerland.

Received: 18 May 2021 Accepted: 28 May 2021

Published online: 22 June 2021

References

- Diether NE, Willing BP (2019) Microbial fermentation of dietary protein: an important factor in diet–microbe–host interaction. *Microorganisms* 7:19. <https://doi.org/10.3390/microorganisms7010019>
- Rychlik I (2020) Composition and function of chicken gut microbiota. *Animals* 10:103. <https://doi.org/10.3390/ani10010103>
- Diaz Carrasco JM, Casanova NA, Fernández Miyakawa ME (2019) Microbiota, gut health and chicken productivity: what is the connection? *Microorganisms* 7:374. <https://doi.org/10.3390/microorganisms7100374>
- Abdelhamid MK, Quijada NM, Dzieciol M, Hatfaludi T, Bilic I, Selberherr E, Liebhart D, Hess C, Hess M, Paudel S (2020) Co-infection of chicken layers with *Histomonas meleagridis* and avian pathogenic *Escherichia coli* is associated with dysbiosis, cecal colonization and translocation of the bacteria from the gut lumen. *Front Microbiol* 11:586437. <https://doi.org/10.3389/fmicb.2020.586437>
- Ruhnau D, Hess C, Grenier B, Doupovec B, Schatzmayr D, Hess M, Awad WA (2020) The Mycotoxin Deoxynivalenol (DON) promotes *Campylobacter jejuni* multiplication in the intestine of broiler chickens with consequences on bacterial translocation and gut integrity. *Front Vet Sci* 7:1027. <https://doi.org/10.3389/fvets.2020.573894>
- Shang Y, Kumar S, Oakley B, Kim WK (2018) Chicken gut microbiota: importance and detection technology. *Front Vet Sci* 5:254. <https://doi.org/10.3389/fvets.2018.00254>
- Kempf F, Menanteau P, Rychlik I, Kubasová T, Trotureau J, Virlogeux-Payant I, Schaeffer S, Schouler C, Drumo R, Guitton E (2020) Gut microbiota composition before infection determines the *Salmonella* super- and low-shedder phenotypes in chicken. *Microb Biotechnol* 13:1611–1630. <https://doi.org/10.1111/1751-7915.13621>
- Hankel J, Jung K, Kuder H, Keller B, Keller C, Galvez E, Strowig T, Visscher C (2019) Caecal microbiota of experimentally *Campylobacter jejuni*-infected chickens at different ages. *Front Microbiol* 10:2303. <https://doi.org/10.3389/fmicb.2019.02303>
- Chen H-L, Zhao X-Y, Zhao G-X, Huang H-B, Li H-R, Shi C-W, Yang W-T, Jiang Y-L, Wang J-Z, Ye L-P (2020) Dissection of the cecal microbial community in chickens after *Eimeria tenella* infection. *Parasit Vectors* 13:56. <https://doi.org/10.1186/s13071-020-3897-6>
- Macdonald SE, Nolan MJ, Harman K, Boulton K, Hume DA, Tomley FM, Stabler RA, Blake DP (2017) Effects of *Eimeria tenella* infection on chicken caecal microbiome diversity, exploring variation associated with severity of pathology. *PLoS One* 12:e0184890. <https://doi.org/10.1371/journal.pone.0184890>
- Wilkinson TJ, Cowan A, Vallin H, Onime L, Oyama LB, Cameron S, Gonot C, Moorby J, Waddams K, Theobald V (2017) Characterization of the microbiome along the gastrointestinal tract of growing turkeys. *Front Microbiol* 8:1089. <https://doi.org/10.3389/fmicb.2017.01089>
- D'Andrea S, Bonastre AS, Francino O, Martí AC, Lecchi C, Grilli G, Giovanardi D, Ceciliani F (2017) Gastrointestinal microbial population of turkey (*Meleagris gallopavo*) affected by hemorrhagic enteritis virus. *Poult Sci* 96:3550–3558. <https://doi.org/10.3382/ps/pex139>
- Danzeisen JL, Clayton JB, Huang H, Knights D, McComb B, Hayer SS, Johnson TJ (2015) Temporal relationships exist between cecum, ileum, and litter bacterial microbiomes in a commercial turkey flock, and subtherapeutic penicillin treatment impacts ileum bacterial community establishment. *Front Vet Sci* 2:56. <https://doi.org/10.3389/fvets.2015.00056>
- Adhikari B, Tellez-Isaias G, Jiang T, Wooming B, Kwon YM (2020) Comprehensive survey of the litter bacterial communities in commercial turkey farms. *Front Vet Sci* 7:596933. <https://doi.org/10.3389/fvets.2020.596933>
- Taylor KJ, Ngunjiri JM, Abundo MC, Jang H, Elaihs M, Ghorbani A, Mahesh K, Weber BP, Johnson TJ, Lee C-W (2020) Respiratory and gut microbiota in commercial turkey flocks with disparate weight gain trajectories display differential compositional dynamics. *Appl Environ Microbiol* 86:e00431–20. <https://doi.org/10.1128/AEM.00431-20>
- Gonzalez-Ortiz G, Olukosi O, Jurgens G, Apajalhti J, Bedford M (2020) Short-chain fatty acids and ceca microbiota profiles in broilers and turkeys in response to diets supplemented with phytase at varying concentrations, with or without xylanase. *Poult Sci* 99:2068–2077. <https://doi.org/10.1016/j.psj.2019.11.051>
- Danzeisen JL, Calvert AJ, Noll SL, McComb B, Sherwood JS, Logue CM, Johnson TJ (2013) Succession of the turkey gastrointestinal bacterial microbiome related to weight gain. *PeerJ* 1:e237. <https://doi.org/10.7717/peerj.237>
- Ballou AL, Ali RA, Mendoza MA, Ellis J, Hassan HM, Croom W, Koci MD (2016) Development of the chick microbiome: how early exposure influences future microbial diversity. *Front Vet Sci* 3:2. <https://doi.org/10.3389/fvets.2016.00002>
- Leitner G, Heller E (1992) Colonization of *Escherichia coli* in young turkeys and chickens. *Avian Dis* 36:211–220
- Hafez HM (2005) Current knowledge and prospective risk analysis related to ongoing turkey disease. In: Proceedings of 14 international congress of the World Poultry Association. Istanbul, Turkey, pp 138–149
- Sárközy G, Semjén G, Laczay P, Horváth E, Schmidt J (2002) Pulse and continuous oral norfloxacin treatment of experimentally induced *Escherichia coli* infection in broiler chicks and turkey poults. *Acta Vet Acad Sci Hung* 50:199–210. <https://doi.org/10.1556/AVet.50.2002.2.9>
- De Oliveira AL, Newman DM, Sato Y, Noel A, Rauk B, Nolan LK, Barbieri NL, Logue CM (2020) Characterization of avian pathogenic *Escherichia coli* (APEC) associated with turkey cellulitis in Iowa. *Front Vet Sci* 7:380. <https://doi.org/10.3389/fvets.2020.00380>
- Collingwood C, Kemmett K, Williams N, Wigley P (2014) Is the concept of avian pathogenic *Escherichia coli* as a single pathotype fundamentally flawed? *Front Vet Sci* 1:5. <https://doi.org/10.3389/fvets.2014.00005>
- Huff G, Huff W, Balog J, Rath N, Anthony N, Nestor K (2005) Stress response differences and disease susceptibility reflected by heterophil to lymphocyte ratio in turkeys selected for increased body weight. *Poult Sci* 84:709–717. <https://doi.org/10.1093/ps/84.5.709>
- Huff G, Huff W, Rath N, Balog J, Anthony N, Nestor K (2006) Stress-induced colibacillosis and turkey osteomyelitis complex in turkeys selected for increased body weight. *Poult Sci* 85:266–272. <https://doi.org/10.1093/ps/85.2.266>
- Umar S, Delverdier M, Delpont M, Belkasmí SF, Teillaud A, Bleuart C, Pardo I, El Houadfi M, Guérin J-L, Ducatez MF (2018) Co-infection of turkeys with *Escherichia coli* (O78) and H6N1 avian influenza virus. *Avian Pathol* 47:314–324. <https://doi.org/10.1080/03079457.2018.1449942>
- Turpin EA, Perkins LE, Swayne DE (2002) Experimental infection of turkeys with avian pneumovirus and either newcastle disease virus or *Escherichia coli*. *Avian Dis* 46:412–422. [https://doi.org/10.1637/0005-2086\(2002\)046\[0412:EIOTWA\]2.0.CO;2](https://doi.org/10.1637/0005-2086(2002)046[0412:EIOTWA]2.0.CO;2)
- Ganas P, Liebhart D, Glösmann M, Hess C, Hess M (2012) *Escherichia coli* strongly supports the growth of *Histomonas meleagridis*, in a monoxenic

- culture, without influence on its pathogenicity. *Int J Parasitol* 42:893–901. <https://doi.org/10.1016/j.ijpara.2012.07.007>
29. Lagler J, Schmidt S, Mitra T, Stadler M, Wernsdorf P, Graf B, Hatfaludi T, Hess M, Gerner W, Liebhart D (2021) Comparative investigation of IFN- γ -producing T cells in chickens and turkeys following vaccination and infection with the extracellular parasite *Histomonas meleagridis*. *Dev Comp Immunol* 116:103949. <https://doi.org/10.1016/j.dci.2020.103949>
 30. Windisch M, Hess M (2010) Experimental infection of chickens with *Histomonas meleagridis* confirms the presence of antibodies in different parts of the intestine. *Parasite Immunol* 32:29–35. <https://doi.org/10.1111/j.1365-3024.2009.01159.x>
 31. Bolger AM, Lohse M, Usadel B (2014) Trimmomatic: a flexible trimmer for Illumina sequence data. *Bioinformatics* 30:2114–2120. <https://doi.org/10.1093/bioinformatics/btu170>
 32. Caporaso JG, Kuczynski J, Stombaugh J, Bittinger K, Bushman FD, Costello EK, Fierer N, Pena AG, Goodrich JK, Gordon JI (2010) QIIME allows analysis of high-throughput community sequencing data. *Nat Methods* 7:335–336. <https://doi.org/10.1038/nmeth.f.303>
 33. Kidane FA, Mitra T, Wernsdorf P, Hess M, Liebhart D (2018) Allocation of interferon gamma mRNA positive cells in caecum hallmarks a protective trait against histomoniasis. *Front Immunol* 9:1164. <https://doi.org/10.3389/fimmu.2018.01164>
 34. Bilic I, Hess M (2020) Interplay between *Histomonas meleagridis* and bacteria: mutualistic or predator–prey? *Trends Parasitol* 36:232–235. <https://doi.org/10.1016/j.pt.2019.12.015>
 35. Kittana H, Gomes-Neto JC, Heck K, Geis AL, Segura Muñoz RR, Cody LA, Schmaltz RJ, Bindels LB, Sinha R, Hostetter JM (2018) Commensal *Escherichia coli* strains can promote intestinal inflammation via differential interleukin-6 production. *Front Immunol* 9:2318. <https://doi.org/10.3389/fimmu.2018.02318>
 36. Zhou B-h, Jia L-s, Wei S-s, Ding H-y, Yang J-y, Wang H-w (2020) Effects of *Eimeria tenella* infection on the barrier damage and microbiota diversity of chicken caecum. *Poult Sci* 99:1297–1305. <https://doi.org/10.1016/j.psj.2019.10.073>
 37. Huang G, Tang X, Bi F, Hao Z, Han Z, Suo J, Zhang S, Wang S, Duan C, Yu Z (2018) *Eimeria tenella* infection perturbs the chicken gut microbiota from the onset of oocyst shedding. *Vet Parasitol* 258:30–37. <https://doi.org/10.1016/j.vetpar.2018.06.005>
 38. Kers JG, Velkers FC, Fischer EA, Hermes GD, Stegeman JA, Smidt H (2018) Host and environmental factors affecting the intestinal microbiota in chickens. *Front Microbiol* 9:235. <https://doi.org/10.3389/fmicb.2018.00235>
 39. Ueki A, Goto K, Ohtaki Y, Kaku N, Ueki K (2017) Description of *Anaerotignum aminivorans* gen. nov., sp. nov., a strictly anaerobic, amino-acid-decomposing bacterium isolated from a methanogenic reactor, and reclassification of *Clostridium propionicum*, *Clostridium neopropionicum* and *Clostridium lactatifermentans* as species of the genus *Anaerotignum*. *Int J Syst Evol Microbiol* 67:4146–4153. <https://doi.org/10.1099/ijsem.0.002268>
 40. Sentfies-Cué G, Chin R, Shivaprasad H (2009) Systemic histomoniasis associated with high mortality and unusual lesions in the bursa of Fabricius, kidneys, and lungs in commercial turkeys. *Avian Dis* 53:231–238. <https://doi.org/10.1637/8363-051508-Reg.1>
 41. Hoda SA, Cheng E (2017) Robbins basic pathology. *Am J Clin Pathol* 148:557. <https://doi.org/10.1093/ajcp/aqx095>
 42. Macfarlane G, Cummings J, Macfarlane S, Gibson G (1989) Influence of retention time on degradation of pancreatic enzymes by human colonic bacteria grown in a 3-stage continuous culture system. *J Appl Microbiol* 67:521–527
 43. Hartley MG, Ralph E, Norville IH, Prior JL, Atkins TP (2019) Comparison of PCR and viable count as a method for enumeration of bacteria in an A/J mouse aerosol model of Q Fever. *Front Microbiol* 10:1552. <https://doi.org/10.3389/fmicb.2019.01552>
 44. Sokol H, Pigneur B, Watterlot L, Lakhdari O, Bermúdez-Humarán LG, Gratadoux J-J, Blugeon S, Bridonneau C, Furet J-P, Corthier G (2008) *Faecalibacterium prausnitzii* is an anti-inflammatory commensal bacterium identified by gut microbiota analysis of crohn disease patients. *Proc Natl Acad Sci* 105:16731–16736
 45. Yan W, Sun C, Yuan J, Yang N (2017) Gut metagenomic analysis reveals prominent roles of *Lactobacillus* and cecal microbiota in chicken feed efficiency. *Sci Rep* 7:45308. <https://doi.org/10.1038/srep45308>
 46. Galperin MY (2013) Genome diversity of spore-forming firmicutes. *Microbiol Spectr*. <https://doi.org/10.1128/microbiolspectrum.TBS-0015-2012>
 47. Medvecky M, Cejkova D, Polansky O, Karasova D, Kubasova T, Cizek A, Rychlik I (2018) Whole genome sequencing and function prediction of 133 gut anaerobes isolated from chicken caecum in pure cultures. *BMC Genom* 19:561. <https://doi.org/10.1186/s12864-018-4959-4>
 48. Khan MT, Duncan SH, Stams AJ, Van Dijk JM, Flint HJ, Harmsen HJ (2012) The gut anaerobe *Faecalibacterium prausnitzii* uses an extracellular electron shuttle to grow at oxic–anoxic interphases. *ISME J* 6:1578–1585. <https://doi.org/10.1038/ismej.2012.5>
 49. Duncan SH, Hold GL, Harmsen HJ, Stewart CS, Flint HJ (2002) Growth requirements and fermentation products of *Fusobacterium prausnitzii*, and a proposal to reclassify it as *Faecalibacterium prausnitzii* gen. nov., comb. nov. *Int J Syst Evol Microbiol* 52:2141–2146. <https://doi.org/10.1099/00207713-52-6-2141>
 50. Hessenberger S, Schatzmayr G, Teichmann K (2016) In vitro inhibition of *Eimeria tenella* sporozoite invasion into host cells by probiotics. *Vet Parasitol* 229:93–98. <https://doi.org/10.1016/j.vetpar.2016.10.001>
 51. Dalloul RA, Lillehoj HS, Tamim NM, Shellem TA, Doerr JA (2005) Induction of local protective immunity to *Eimeria acervulina* by a *Lactobacillus*-based probiotic. *Comp Immunol Microbiol Infect Dis* 28:351–361. <https://doi.org/10.1016/j.cimid.2005.09.001>
 52. Gong J, Si W, Forster RJ, Huang R, Yu H, Yin Y, Yang C, Han Y (2007) 16S rRNA gene-based analysis of mucosa-associated bacterial community and phylogeny in the chicken gastrointestinal tracts: from crops to ceca. *FEMS Microbiol Ecol* 59:147–157. <https://doi.org/10.1111/j.1574-6941.2006.00193.x>
 53. Johnson TA, Sylte MJ, Looft T (2019) In-feed bacitracin methylene disalicylate modulates the turkey microbiota and metabolome in a dose-dependent manner. *Sci Rep* 9:8212. <https://doi.org/10.1038/s41598-019-44338-5>
 54. Palestrant D, Holzknacht ZE, Collins BH, Parker W, Miller SE, Bollinger RR (2004) Microbial biofilms in the gut: visualization by electron microscopy and by acridine orange staining. *Ultrastruct Pathol* 28:23–27

Publisher's Note

Springer Nature remains neutral with regard to jurisdictional claims in published maps and institutional affiliations.